

# Objective Assessment of the Quality of Vision Before and After Repositioning of a Dislocated Iris-fixated Aphakic Anterior Chamber Lens

Damien Gatinel, MD, PhD; Thanh Hoang-Xuan, MD

## ABSTRACT

**PURPOSE:** To document severe visual symptoms due to the dislocation of an iris-fixated aphakic anterior chamber lens using wavefront aberrometry.

**METHODS:** A patient complaining of severe visual blur and distortion due to a decentered Artisan iris-fixated anterior chamber lens was evaluated pre- and postoperatively after recenteration. The patient underwent complete ophthalmic evaluation including the measurement of corneal topography and wavefront aberrations using the NIDEK OPD-Scan. OPD Station software was used to correlate and simulate the patient's symptoms.

**RESULTS:** After the repositioning procedure, the visual symptoms resolved, and high magnitudes of tilt ( $7.536 \mu\text{m}$ ) and high order aberrations ( $5.129 \mu\text{m}$ ) were dramatically reduced by simple lens repositioning (4.40-mm pupil). The cylinder magnitude was reduced from 6.25 to 0.75 diopters.

**CONCLUSIONS:** These are the first diagnostic images of this kind in a highly aberrated eye with iris-fixated anterior chamber lens dislocation. The images documented the optical effect and visual consequences of IOL decentration and subsequent recenteration. [*J Refract Surg.* 2007;23:Sxxx-Sxxx.]

**D**ecentration is a rare but serious complication of intraocular lens (IOL) implantation, which can result in a variety of photopic and scotopic symptoms such as glare, monocular diplopia, and even phoria due to induced prism. Recent advances in IOL technology such as the introduction of aspheric and corneal wavefront-guided IOLs have garnered interest on the consequences of IOL decentration. However, the objective optical consequences of severe IOL decentration have not been reported extensively.

In this case report, we document and explain the severe visual degradation due to the dislocation of an Artisan iris-fixated anterior chamber IOL that was successfully treated by lens repositioning. To document the optical and visual quality pre- and postoperatively, we used the NIDEK OPD-Scan wavefront aberrometer and corneal topographer (NIDEK Co Ltd, Gamagori, Japan). To our knowledge, this is the first extensive diagnostic and prognostic analysis of this kind where extensive optical quality analysis was performed before and after surgical repositioning of a dislocated IOL.

## METHODS

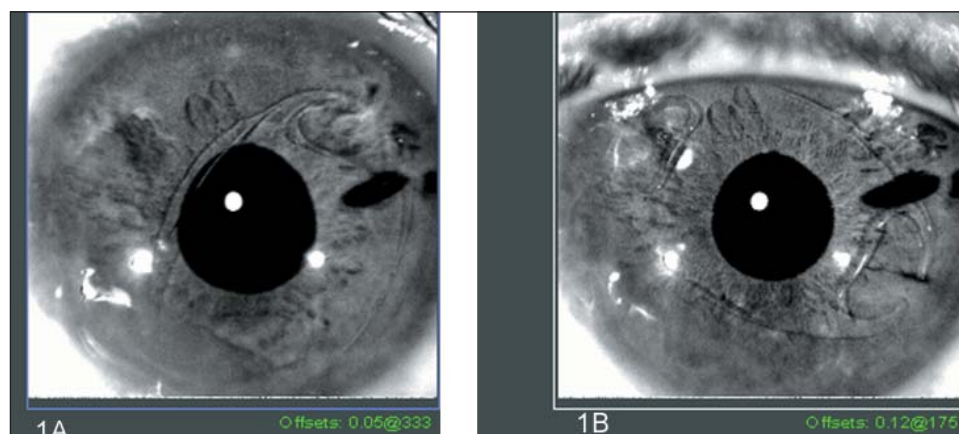
### CASE REPORT

A 68-year-old man presented with a progressive loss of visual acuity and disturbing visual symptoms in his left eye 6 months prior to visiting our clinic. Medical history was unremarkable. Ocular history was unremarkable for the right eye; however, the left eye had undergone anterior chamber IOL implantation 2 years prior to presentation. An 18.00-diopter (D) Artisan iris-fixated anterior chamber lens (Ophtec Inc, Groningen, The Netherlands) was implanted to correct aphakia secondary to complicated extracapsular cataract extraction. Per review of the patient's previous records it was determined that the original implant was properly centered.

*From the Rothschild Foundation and AP-HP Bichat Claude Bernard, Paris VII University, Paris, France.*

*The authors have no financial interest in any of the products mentioned.*

*Correspondence: Damien Gatinel, MD, PhD, 25 rue Manin, 75019 Paris, France. E-mail: gatinel@aol.com*



**Figure 1.** OPD-Scan image of the left eye showing **A)** an inferotemporal dislocation of an anterior chamber IOL and **B)** a well centered lens after iris repositioning and centration.

The uncorrected visual acuity of the left eye was limited to counting fingers (CF) at 1 meter. Best spectacle-corrected visual acuity (BSCVA) was 20/80 with  $+3.00 -6.00 \times 130^\circ$ . The patient complained about severe monocular blur and oblique distortion about bright lights in the left eye that began approximately 1 year prior to examination and progressively worsened over time. Slit-lamp examination revealed a nuclear cataract in the right eye and a dislocated anterior chamber IOL in the left eye due to atrophy of the iris tissue around the enclavation site of the inferior haptic causing haptic escape (Fig 1A). The superior claw was still well intact; however, mild iris atrophy adjacent to the enclavation site was present. The lens had dislocated temporally, with subsequent decentration of the central optic to the pupil rim (Fig 1A). The scleral wound was intact, and the anterior chamber was quiet. Endothelial cell count was 2000 cell/mm<sup>2</sup> in the right eye and 1850 cell/mm<sup>2</sup> in the left eye. Ultrasound corneal pachymetry in both eyes was 535  $\mu$ m. Dilated fundus examination was unremarkable for both eyes.

One day later, the patient underwent surgery to recenter the anterior chamber IOL under topical anesthetic. The Artisan lens was repositioned by removing and enclavating the two claws to the midperiphery of the iris closer to the horizontal direction (Fig 1B).

Visual symptoms had resolved by 1 month postoperatively, and by 3 months postoperatively, BSCVA was 20/30 with  $-4.00 -0.50 \times 50^\circ$ .

#### WAVEFRONT AND CORNEAL TOPOGRAPHY MEASUREMENTS AND VISUAL PERFORMANCE

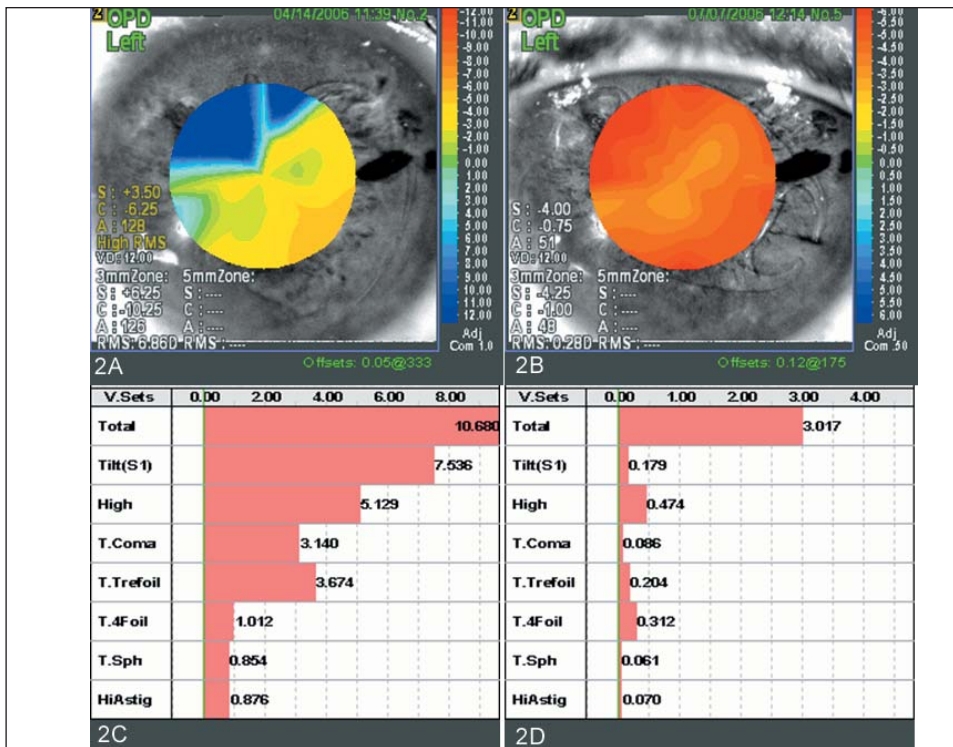
OPD-Scan topography and wavefront analysis were performed preoperatively and 1 month postoperatively in natural pupil conditions to the 6th Zernike order. The measurements were repeated at least three times to obtain a well-focused, properly aligned image of the eye. From the Zernike coefficients of the 27 terms of the Zernike pyramid included in the 6th order decom-

position (excluding the 0<sup>th</sup>=Z<sub>0</sub><sup>0</sup> piston term), the root-mean-square of total aberrations (1st to 27th terms), high order aberrations (all terms included in the 3rd, 4th, 5th, and 6th order), tilt (1st = Z<sub>1</sub><sup>-1</sup> and 2nd = Z<sub>1</sub><sup>1</sup>), coma (7th = Z<sub>3</sub><sup>-1</sup>, 8th = Z<sub>3</sub><sup>1</sup>, 17th = Z<sub>5</sub><sup>-1</sup>, 18th = Z<sub>5</sub><sup>1</sup>), trefoil (6th = Z<sub>3</sub><sup>-3</sup>, 9th = Z<sub>3</sub><sup>3</sup>, 16th = Z<sub>5</sub><sup>-3</sup>, 19th = Z<sub>5</sub><sup>3</sup>), tetrafoil (10th = Z<sub>4</sub><sup>-4</sup>, 14th = Z<sub>4</sub><sup>4</sup>, 22nd = Z<sub>6</sub><sup>-4</sup>, 26th = Z<sub>6</sub><sup>4</sup>), spherical aberration (12th = Z<sub>4</sub><sup>0</sup> and 24th = Z<sub>6</sub><sup>0</sup>), and secondary astigmatism (11th = Z<sub>4</sub><sup>-2</sup>, 13th = Z<sub>4</sub><sup>2</sup>, 23rd = Z<sub>6</sub><sup>-2</sup>, 25th = Z<sub>6</sub><sup>2</sup>) were calculated. The OPD Station software was used to further analyze the acquired data and generate modulation transfer function (MTF) curves to determine the patient's visual performance across low and high spatial frequencies.

#### RESULTS

Figure 2 shows the Optical Path Difference (OPD map) and the wavefront aberrations before and after IOL recenteration. The OPD map displays the distribution of refractive errors within the entrance pupil. It includes the effects of the cornea and IOL. The spherocylindrical parameters (sphere, cylinder, and axis) corresponding to the objective spectacle refraction are also measured at various pupil diameters. Preoperatively, there is an 18.00-D difference in refractive power across the physiologically dilated pupil (4.40 mm) (Fig 2A). Postoperatively, there was a difference of 2.50 D across the physiologically dilated pupil (Fig 2B). The repositioning and recenteration of the IOL reduced the magnitude of refractive cylinder from  $-6.25$  to  $-0.75$  D (see Figs 2A and 2B). The corneal aberrations before and after the anterior chamber IOL recenteration were 0.682  $\mu$ m and 0.670  $\mu$ m, respectively.

Figures 2C and 2D plot the magnitude of the wavefront groups before and after IOL recenteration for the patient's physiologically dilated pupil, which measured 4.40 mm. High magnitudes of tilt (7.536  $\mu$ m) and high order aberrations (5.129  $\mu$ m) were present preoperatively (see Fig 2C). Among high order aberrations,



**Figure 2.** OPD-Scan analysis of the left eye of a patient who underwent anterior chamber IOL repositioning. **A)** Preoperative OPD map plotting the refractive gradient across a pupil. Note the gradient of local refractive error in the inferotemporal direction of 18.00 D. **B)** Postoperative measurement of the refractive gradient across the pupil. The distribution of the refractive power is more uniform. **C)** Preoperative Zernike analysis of the ocular aberrations out to the 6th order. **D)** Postoperative Zernike analysis of the ocular aberrations out to the 6th order. Root-mean-square values in microns are plotted in both Zernike graphs. Aberrations are tabulated for total aberrations (Total), tilt, higher order aberration (High), total coma aberration (T. Coma), total trefoil (T. Trefoil), total quadrafoil (T. 4Foil), total spherical aberration (T. Sph), and higher order astigmatism (HiAstig). All measurements were performed over a physiologically dilated mesopic pupil of 4.40 mm.

coma and trefoil-like aberrations were predominant. The percentage of reduction for each group of aberrations analyzed is indicated in the Table. Repositioning of the IOL reduced the higher order aberrations by a factor of 91%, even larger reductions were seen in coma and tilt (Table).

The higher order aberration point spread function (PSF), convolved Snellen charts, and MTF curves are plotted in Figures 3 and 4. Relocating the anterior chamber IOL resulted in the disappearance of the oblique elongation of the PSF and an improvement in optotype discrimination (see Fig 3). Postoperatively, the area under the MTF curve increased (see Fig 4).

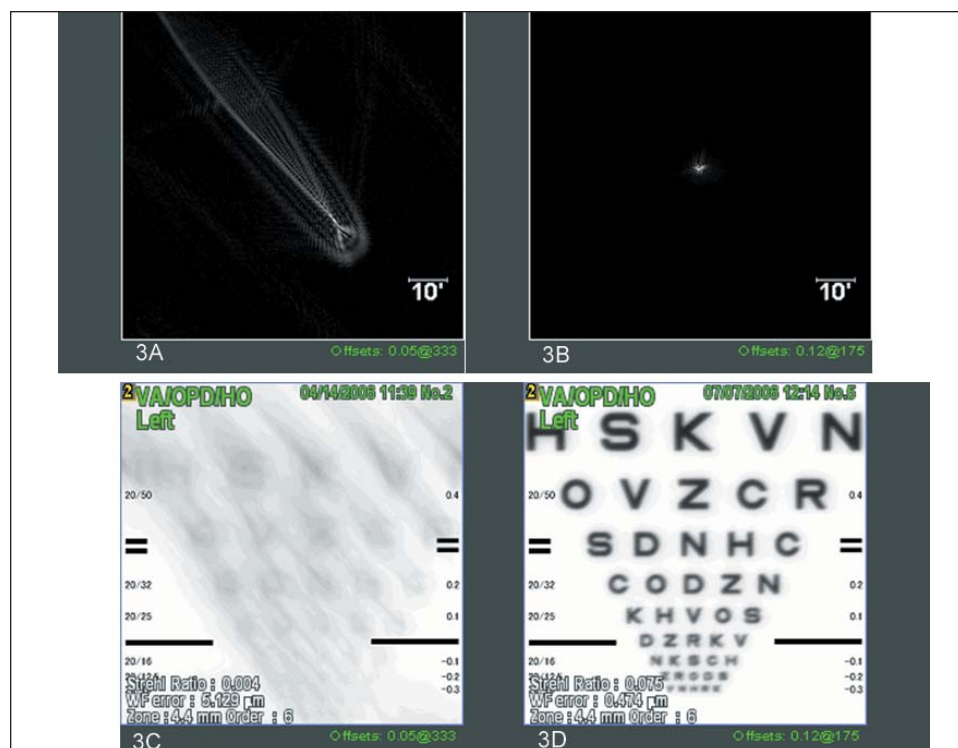
**DISCUSSION**

Although Artisan IOL dislocation has been reported previously,<sup>1,2</sup> its visual consequences have not been extensively investigated or optically documented. In this case report, slit-lamp microscopy and the ocular history indicated that the IOL dislocation probably occurred (at least partially) in a progressive fashion. The magnitude of ocular higher order aberration was extremely high. There was no appreciable change in corneal aberrations before and after IOL repositioning. Hence, the change in ocular aberrations must have been due to the IOL dislocation. The reduction in higher order aberrations allowed a reduction of symptoms as documented in the PSF and the optotype simulation and caused better visual performance postoperatively documented by the MTF curves.

TABLE  
**Percentage Reduction in the Aberrations of an Eye After Anterior Chamber Intraocular Lens Repositioning**

Aberration	Percent Change
Total	-72
Tilt	-98
High	-91
Total coma	-97
Total trefoil	-94
Total quadrafoil	-69
Total spherical aberration	-93
Higher order astigmatism	-92

To our knowledge, this is the highest magnitude of optical aberration measured in the human eye. Such extreme wavefront distortion may exceed the dynamic range of most commercially available Shack-Hartmann-based and Tscherning ocular wavefront analyzers. The OPD-Scan uses the principle of skiascopic phase difference to determine the refractive wavefront of the eye.<sup>3,4</sup> The retina is scanned with an infrared light slit beam, and the reflected light is captured by an array of rotating photodetectors over 360° in 1° increments. Measurements are taken in less than 0.5



**Figure 3.** OPD-Scan analysis of the same patient. **A)** Preoperative higher order point spread function (HO PSF). The oblique elongation of light intensity is predominantly due to odd order aberrations and matches the direction of the axis of decentration of the anterior chamber IOL. **B)** Improvement of the HO PSF after lens repositioning and recentering. **C)** Preoperative convolved Snellen charts simulating the patient's best spectacle-corrected visual acuity (BSCVA) for a 4.40-mm mesopic pupil. **D)** Postoperative convolved Snellen charts simulating the patient's BSCVA for a 4.40-mm mesopic pupil.

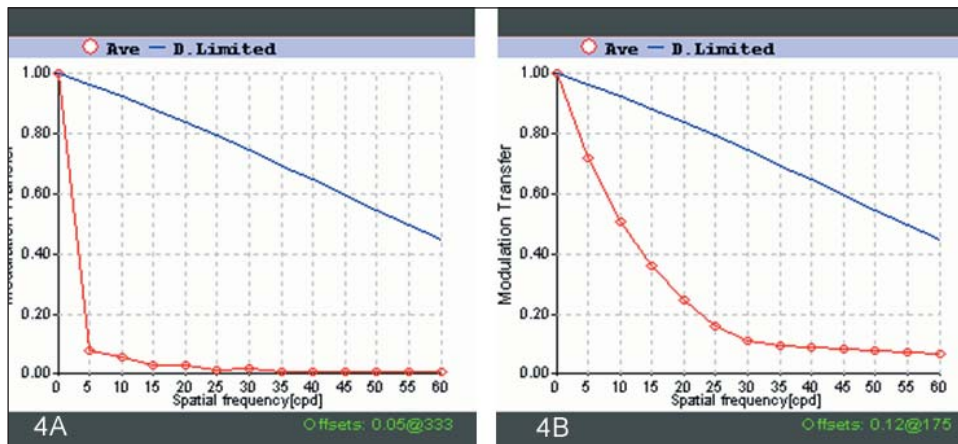
seconds for up to 1440 pupil positions sequentially. The measurement concept is somewhat similar to Placido disc type keratographers in that measurement at any pupil position is in a radial direction only.

Theoretical models have shown that slight physical tilt and decentration of the IOL lead to increased ocular aberrations and refractive errors.<sup>5</sup> These defects also cause residual sphere and cylinder that may adversely affect vision. Indeed, the larger aberration introduced in our case by the IOL decentration was 2nd order astigmatism.

The theoretical effect on ocular wavefront aberrations of moderate (up to 1 mm) decentration of aspherical IOLs and wavefront-corrected IOLs has been investigated.<sup>6</sup> Using Scheimpflug imaging, Taketani et al<sup>7</sup> reported the influence of IOL tilt and decentration measured on wavefront aberrations. They found a significant correlation between the physical tilt of the IOL and coma-like aberrations of the entire eye.<sup>7</sup> They suggested that the physical tilt of the IOL influenced the amount of higher order aberrations.<sup>7</sup> Turuwhenua investigated the theoretical effect of IOL tilt and decentration on perceptual image quality and found that a combination of tilt and decentration produced the greatest loss of contrast.<sup>8</sup> The total decentration of the Artisan IOL from the center of the pupil was estimated from the anterior segment picture to be between 1.00 and 1.10 mm. Given the asymmetrical nature due to the haptic escape of one claw, the Artisan lens was likely tilted with regards to the iris plane, although we

did not measure the physical tilt and decentration of the IOL using Scheimpflug videophotography.

Physical tilt should not be confused with the tilt that denotes prismatic wavefront error. In the Zernike classification scheme, tilt corresponds to a low order aberration (first radial order), which does not induce any distortion of the image but rather a shift in its position. Coma aberration is a high order aberration that arises from less than ideal centration and physical tilt of different refractive interfaces between the entrance pupil and the fovea that results in a “smearing” of the retinal image.<sup>9</sup> The large coma aberration measured in this case may be proportional to the physical tilt and decentration of the IOL optic relative to the plane of the entrance pupil. As opposed to the coma expressed as a Seidel aberration term (which comprises third order terms only), the mathematical coma expressed as a combination of 3rd and 5th order Zernike terms comprises first and third radial order terms to satisfy the mathematical constraint of orthogonality. This would cause the central flatter portion of a theoretical wavefront distorted only by a 3rd or 5th order Zernike coma term to form an important angulation with the plane of the pupil. Comparing the effects of different aberrations, Applegate et al<sup>10</sup> have shown that the more distorted the wavefront centrally, the more deleterious it is to visual performance. We previously postulated that when suffering from coma-like aberration due to imperfect IOL centration or a significant physical tilt, the eyeball may slightly rotate to adjust the line



**Figure 4.** A) Pre- and B) postoperative modulation transfer function (MTF) graphs of the left eye of a patient who underwent anterior chamber IOL repositioning and recentering.

of sight so that a less distorted central region of the wavefront would converge on the fovea.<sup>11</sup> This would therefore result in induction of some tilt. An increase in coma may lead to an increase in tilt, although the relationship between lens tilt and coma may not be linear. Statistical correlation between tilt and 3rd order coma in healthy eyes has been reported.<sup>12</sup> The importance of the measured tilt aberration may thus reflect the amount of coma aberration present in the acquired ocular wavefront, which is in turn proportional to the degree of physical tilt and/or decentration of the anterior chamber IOL. The drastic reduction of the amount of tilt and coma-like aberrations after anterior chamber IOL recentering supports this hypothesis.

This case highlights the clinical use of the OPD-Scan as a robust wavefront sensor, which can provide precise qualitative and quantitative assessment even in clinical situations where the optical quality of the eye is severely compromised. This ability may be particularly interesting in situations where large amounts of wavefront aberrations may occur, such as severe photoablation decentration, penetrating keratoplasty, or advanced keratoconus.

## REFERENCES

1. Yoon H, Macaluso DC, Moshirfar M, Lundergan M. Traumatic dislocation of an Ophtec Artisan phakic intraocular lens. *J Refract Surg.* 2002;18:481-483.
2. Ioannidis A, Nartey I, Little BC. Traumatic dislocation and successful re-encapsulation of an Artisan phakic IOL with analysis of the endothelium. *J Refract Surg.* 2006;22:102-103.
3. Holzer MP, Goebels S, Auffarth GU. Precision of NIDEK OPD-scan measurements. *J Refract Surg.* 2006;22:S1021-S1023.
4. Gatinel D, Hoang-Xuan T. Measurement of combined corneal, internal, and total ocular optical quality analysis in anterior segment pathology with the OPD-scan and OPD-station. *J Refract Surg.* 2006;22:S1014-S1020.
5. Korynta J, Bok J, Cendelin J, Michalova K. Computer modeling of visual impairment caused by intraocular lens misalignment. *J Cataract Refract Surg* 1999;25:100-105.
6. Wang L, Koch DD. Effect of decentration of wavefront-corrected intraocular lenses on the higher-order aberrations of the eye. *Arch Ophthalmol.* 2005;123:1226-1230.
7. Taketani F, Matuura T, Yukawa E, Hara Y. Influence of intraocular lens tilt and decentration on wavefront aberrations. *J Cataract Refract Surg* 2004;30:2158-162.
8. Turuwhenua J. A theoretical study of intraocular lens tilt and decentration on perceptual image quality. *Ophthalmic Physiol Opt.* 2005;25:556-567.
9. Applegate RA, Hilmantel G, Howland HC, Tu EY, Starck T, Zayac EJ. Corneal first surface optical aberrations and visual performance. *J Refract Surg.* 2000;16:507-514.
10. Applegate RA, Sarver EJ, Khemsara V. Are all aberrations equal? *J Refract Surg.* 2002;18:S556-62
11. Rohart C, Lemarinel B, Thanh HX, Gatinel D. Ocular aberrations after cataract surgery with hydrophobic and hydrophilic acrylic intraocular lenses: comparative study. *J Cataract Refract Surg.* 2006;32:1201-1205.
12. Thibos LN, Hong X, Bradley A, Cheng X. Statistical variation of aberration structure and image quality in a normal population of healthy eyes. *J Opt Soc Am A Opt Image Vis Sci.* 2002;19:2329-2348.

**AUTHOR QUERIES**

Was the material in this article presented at a meeting?

What does “optically documented” mean?

Please fax copyright form signed by Dr Hoang-Xuan.